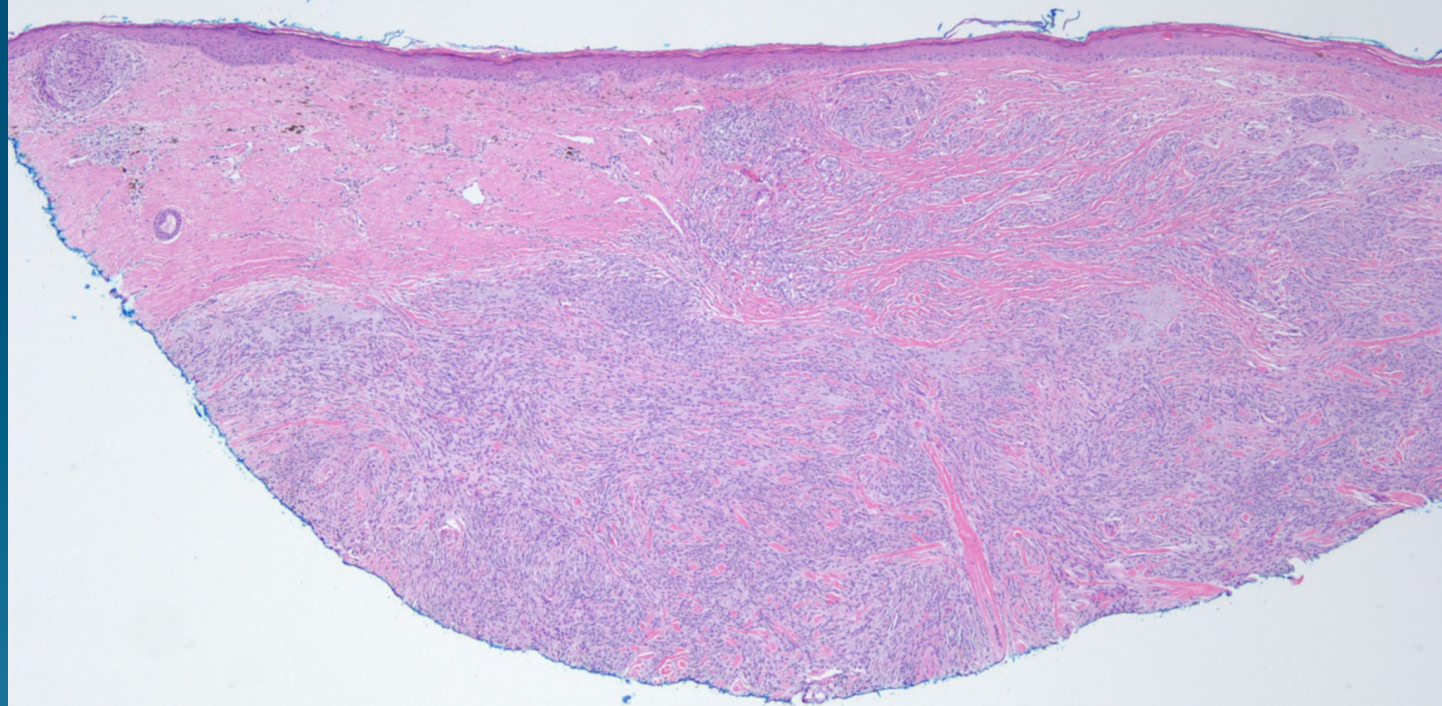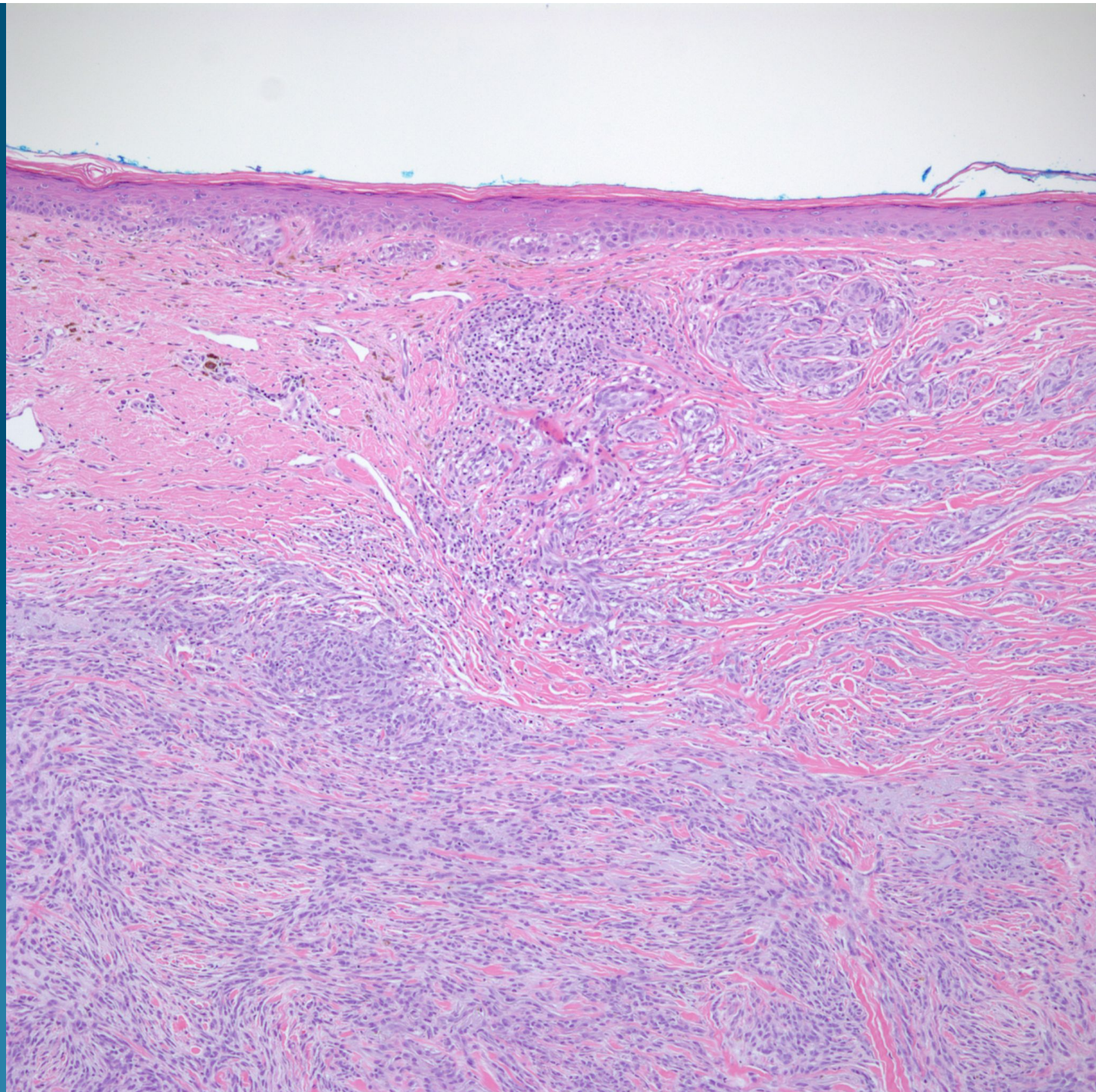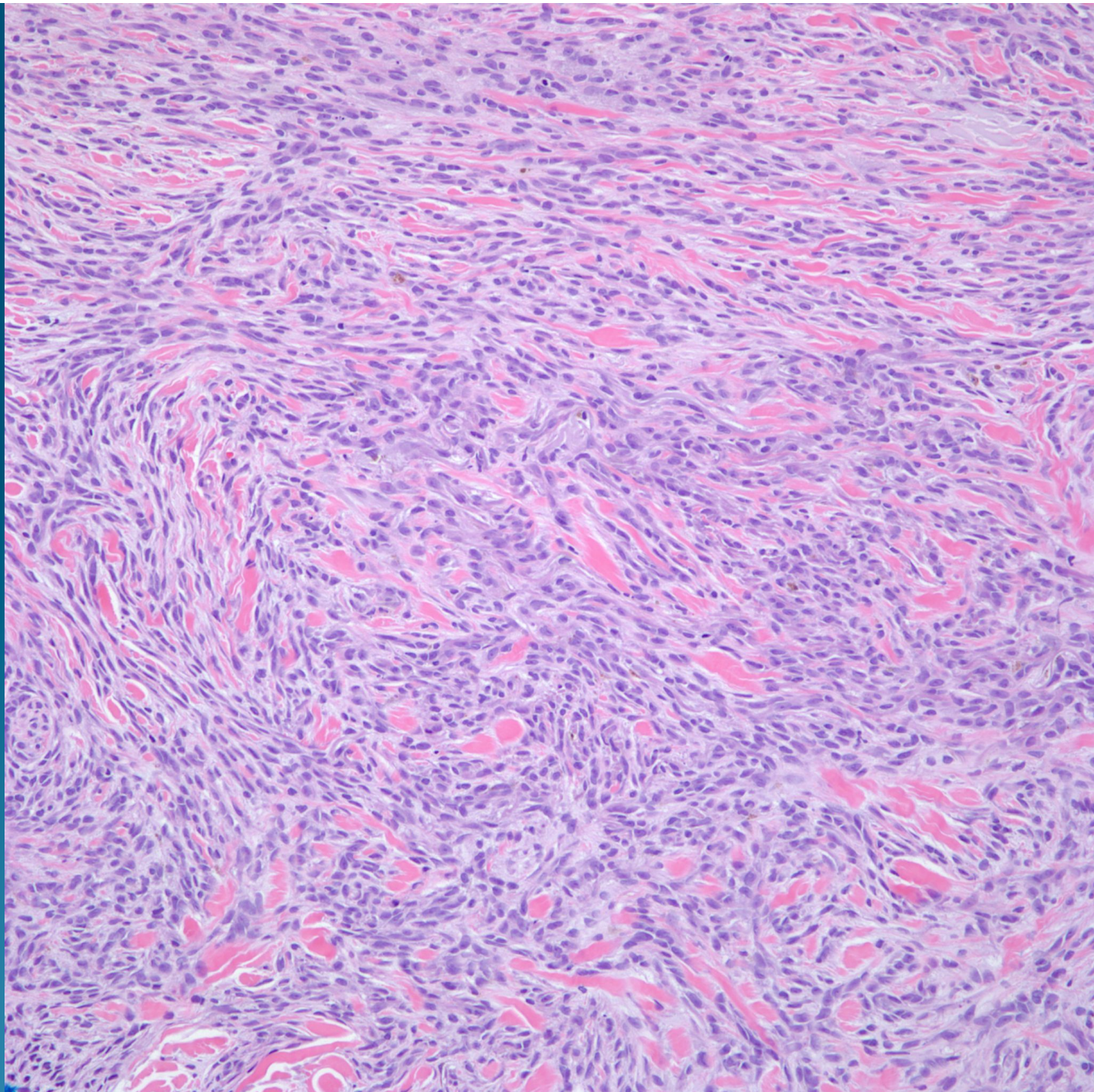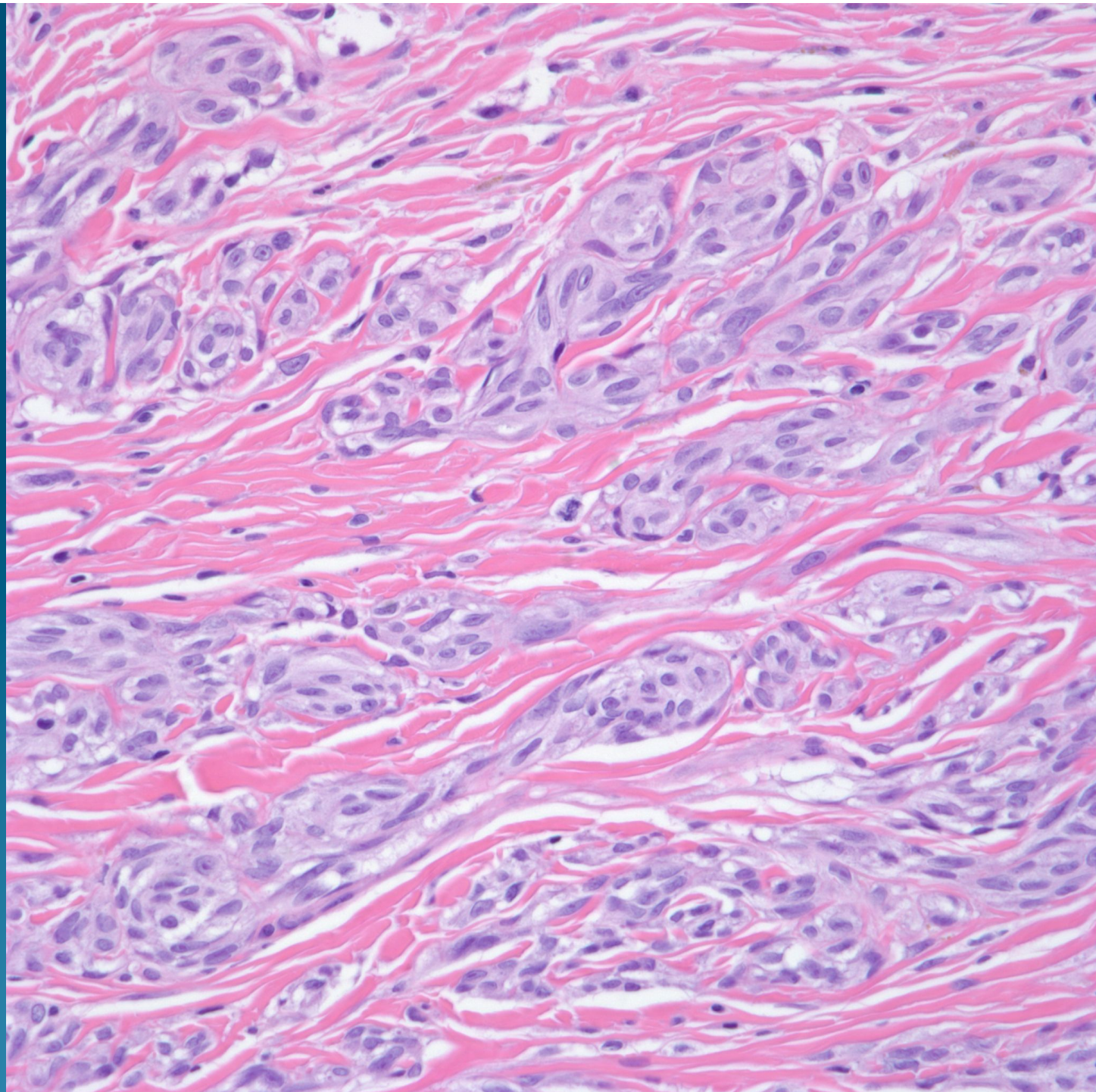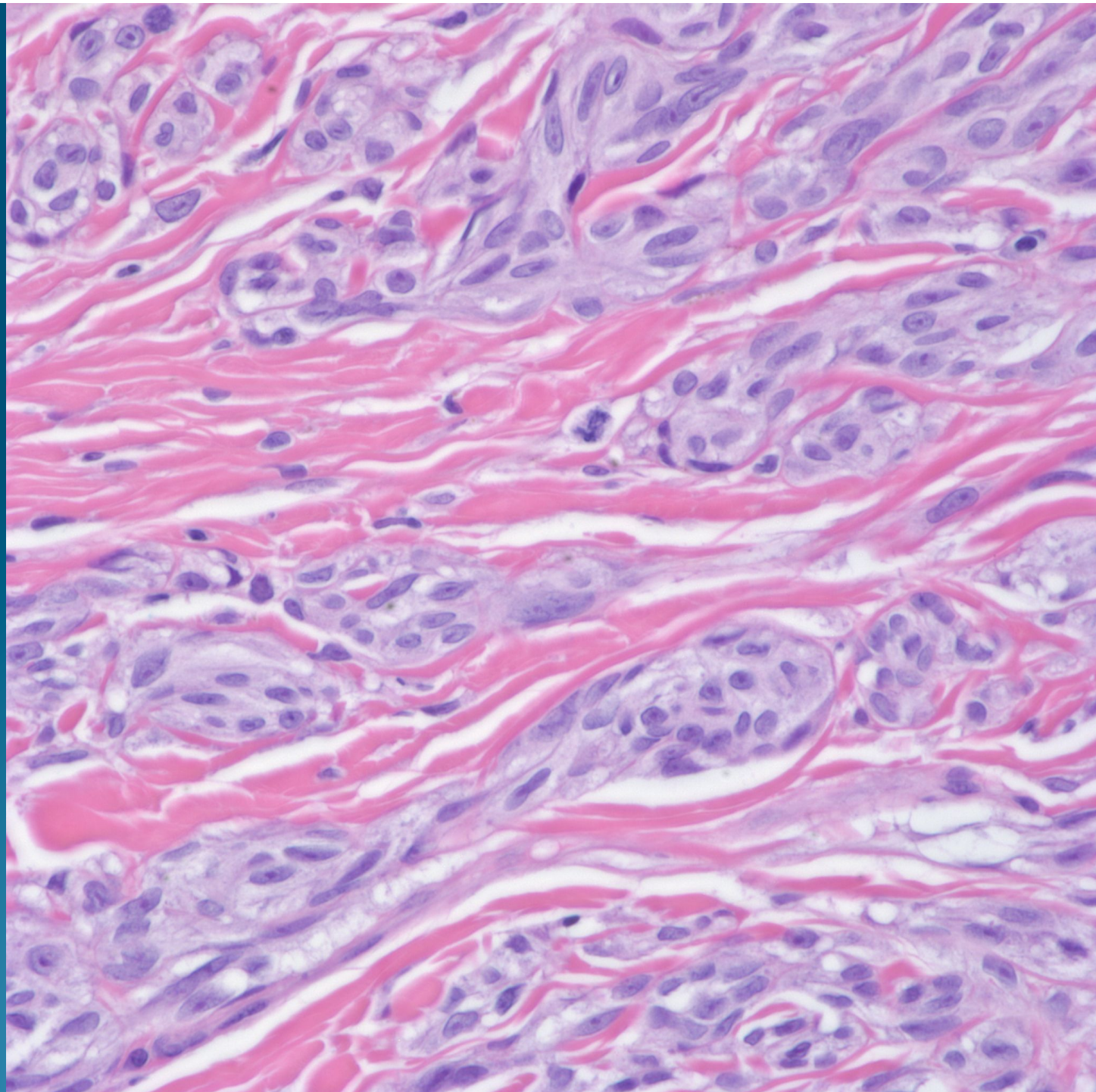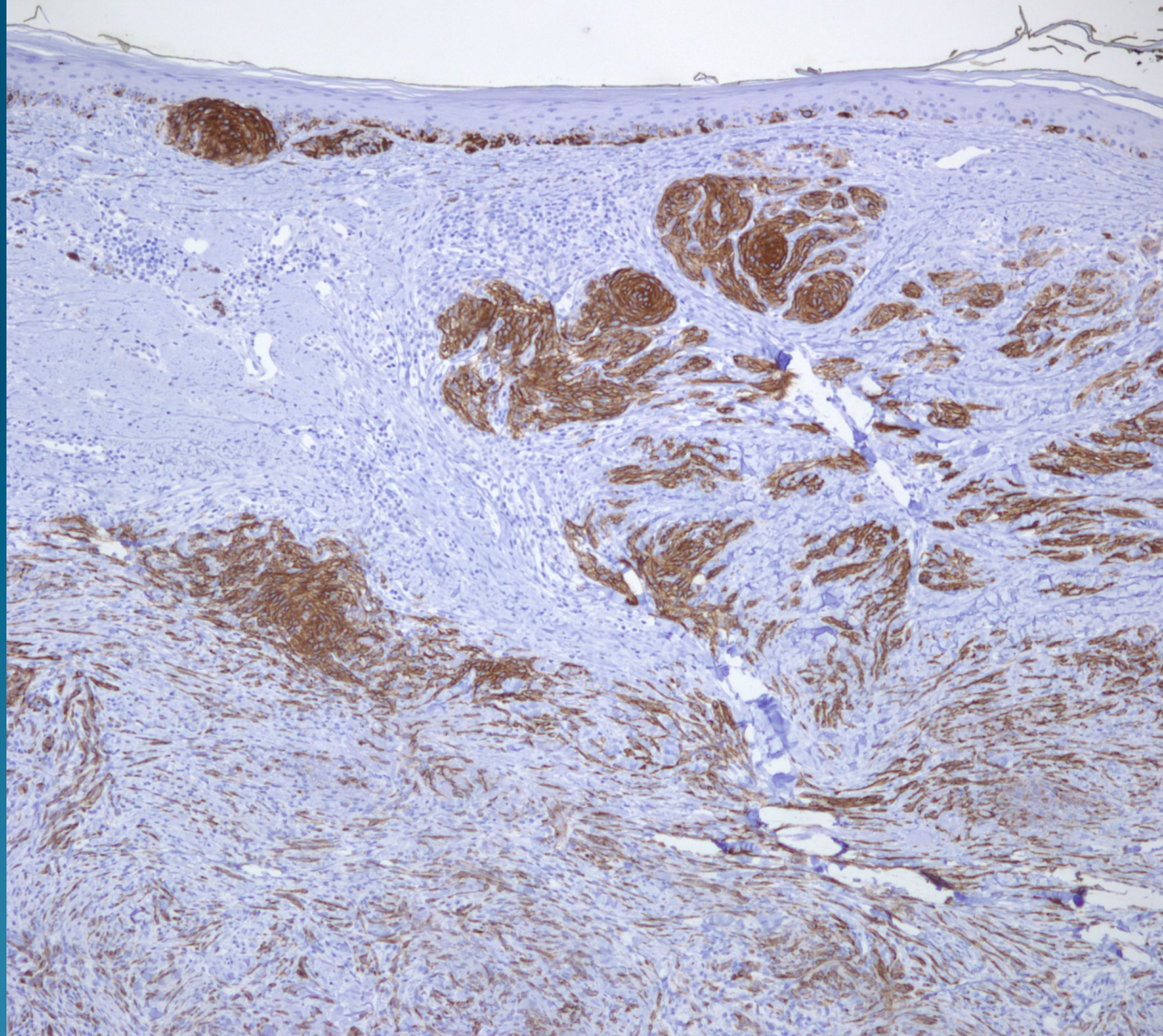


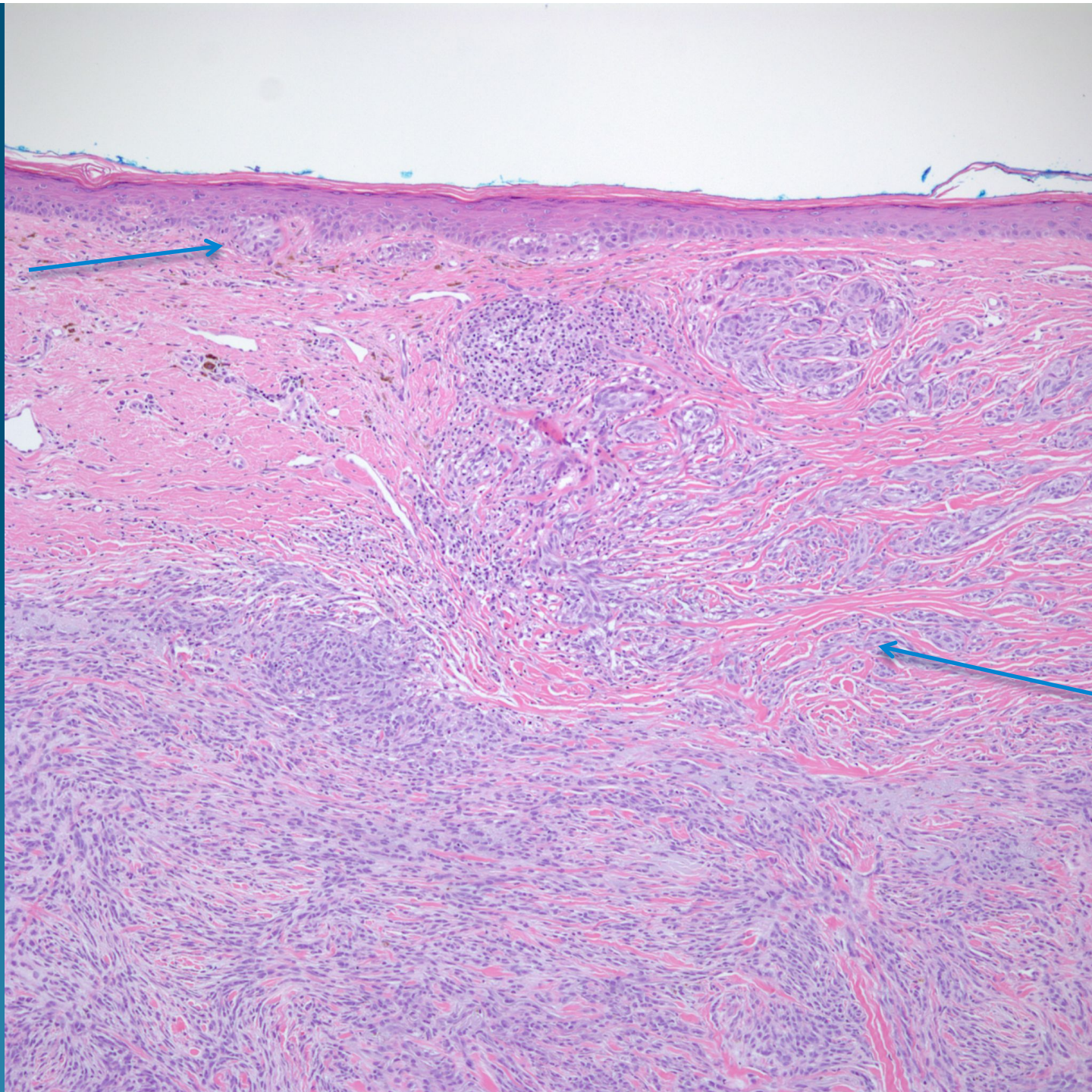
Melan A



Desmoplastic Malignant Melanoma

May have
Junctional
Nests of
Atypical
Melano-
cytes

Minimal
To absent
Melanin
pigment



Atypical
Spindled
cells